TP 3. Diversité des organismes pluricellulaires : Etude d'un poisson Téléostéen, la Truite

Squelette de « Poisson »

O. Mottet

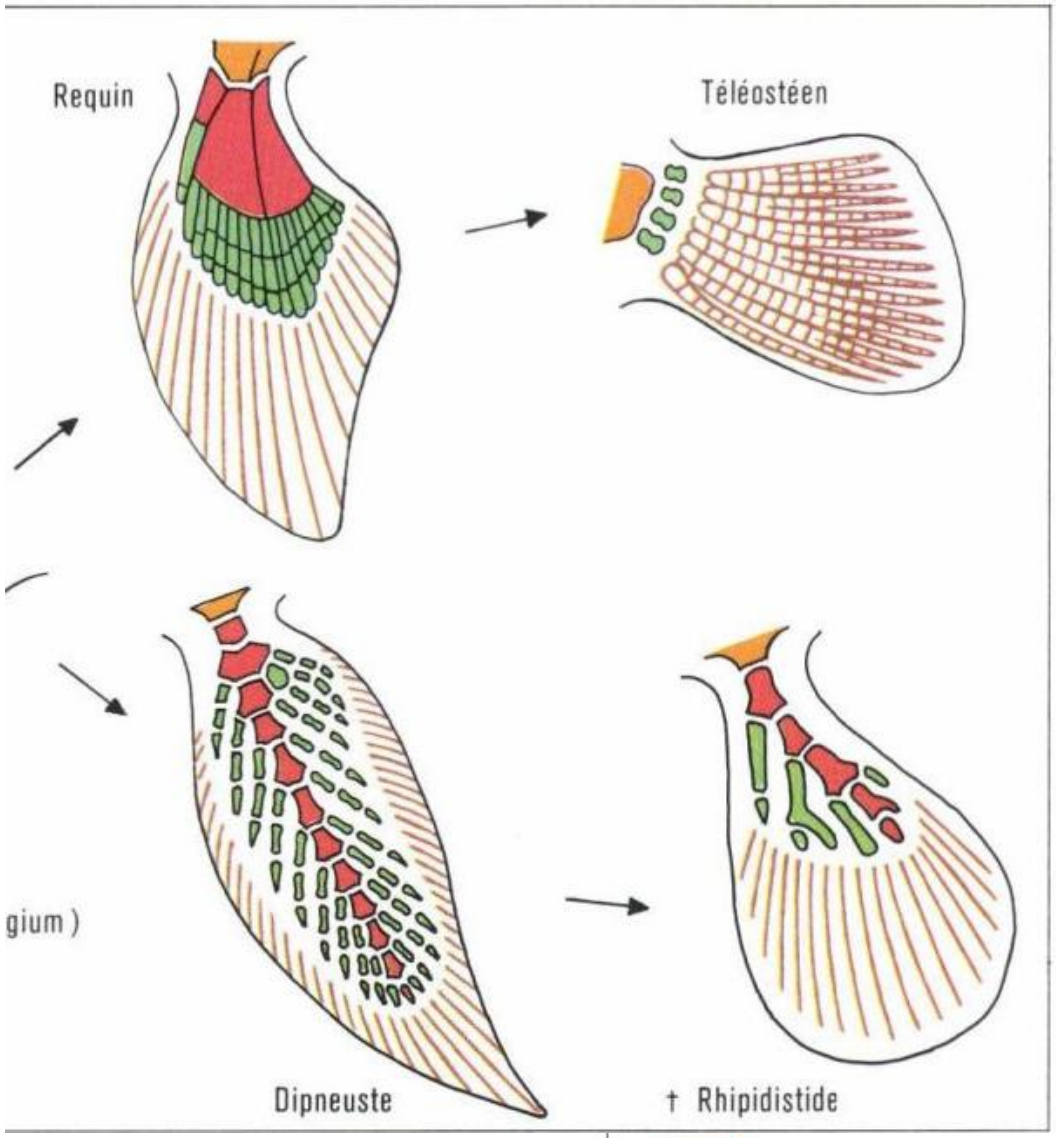

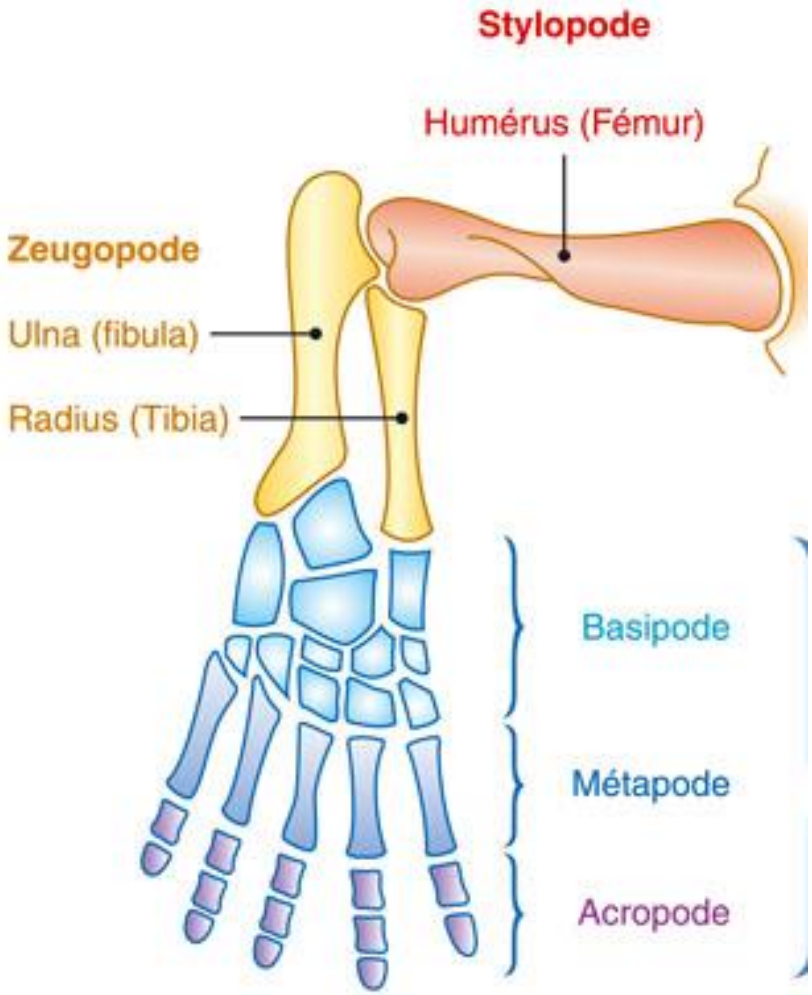

ceinture scapulaire

rayons basaux (basiptérygium) (ou axiaux)

rayons distaux

lépidotriches

La nageoire pectorale des « Poissons » (membre ptérygien)

Le membre chiridien des Vertébrés Tétrapodes

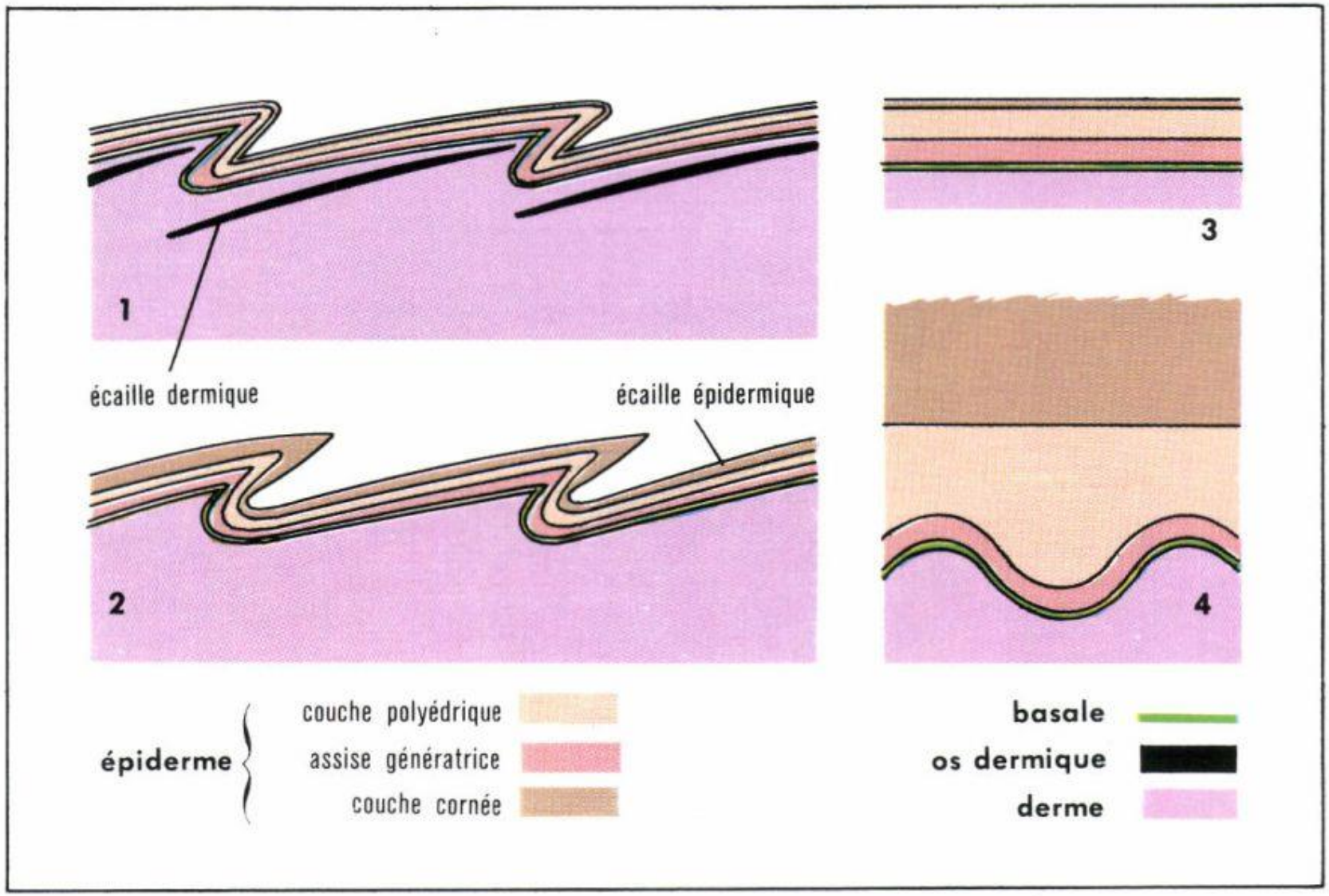

Schémas de téguments de Vertébrés : 1. Poisson; 2. Reptile; 3. Batracien; 4. Homme.

http://www.larousse.fr/archives/grande-encyclopedie/page/13385

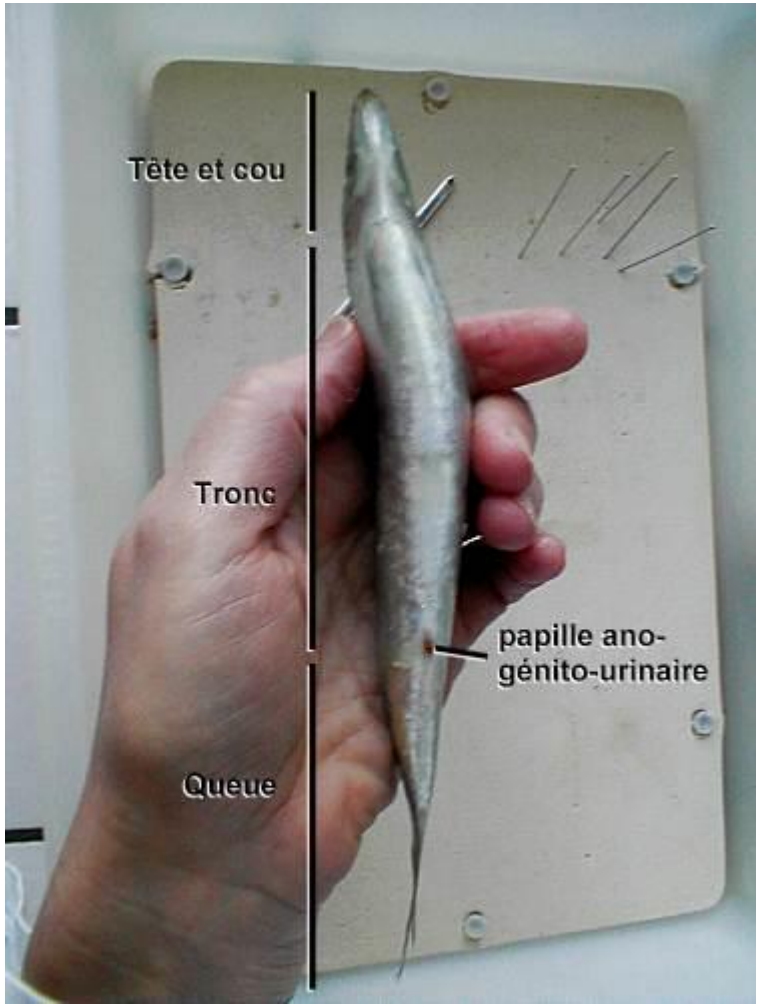

Faire une boutonnière aux ciseaux en avant de la papille ano-génito-urinaire

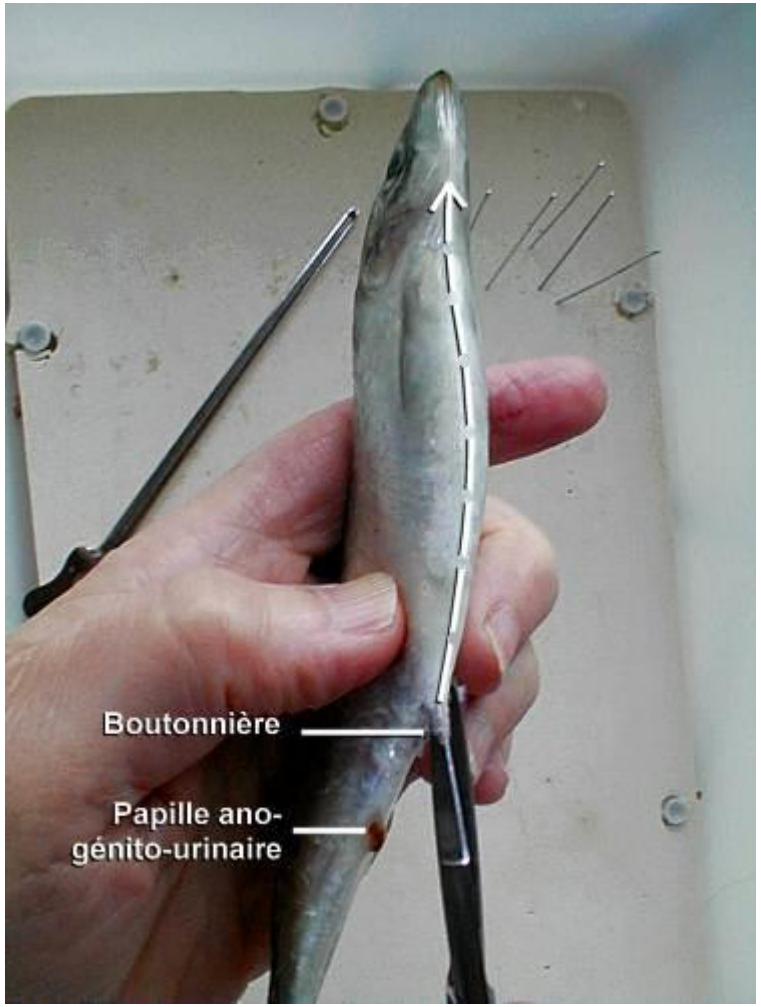

Couper la peau et les muscles jusqu'à la bouche en guidant les ciseaux sans léser les organes sous-jacents (on peut s’aider de la sonde cannelée)

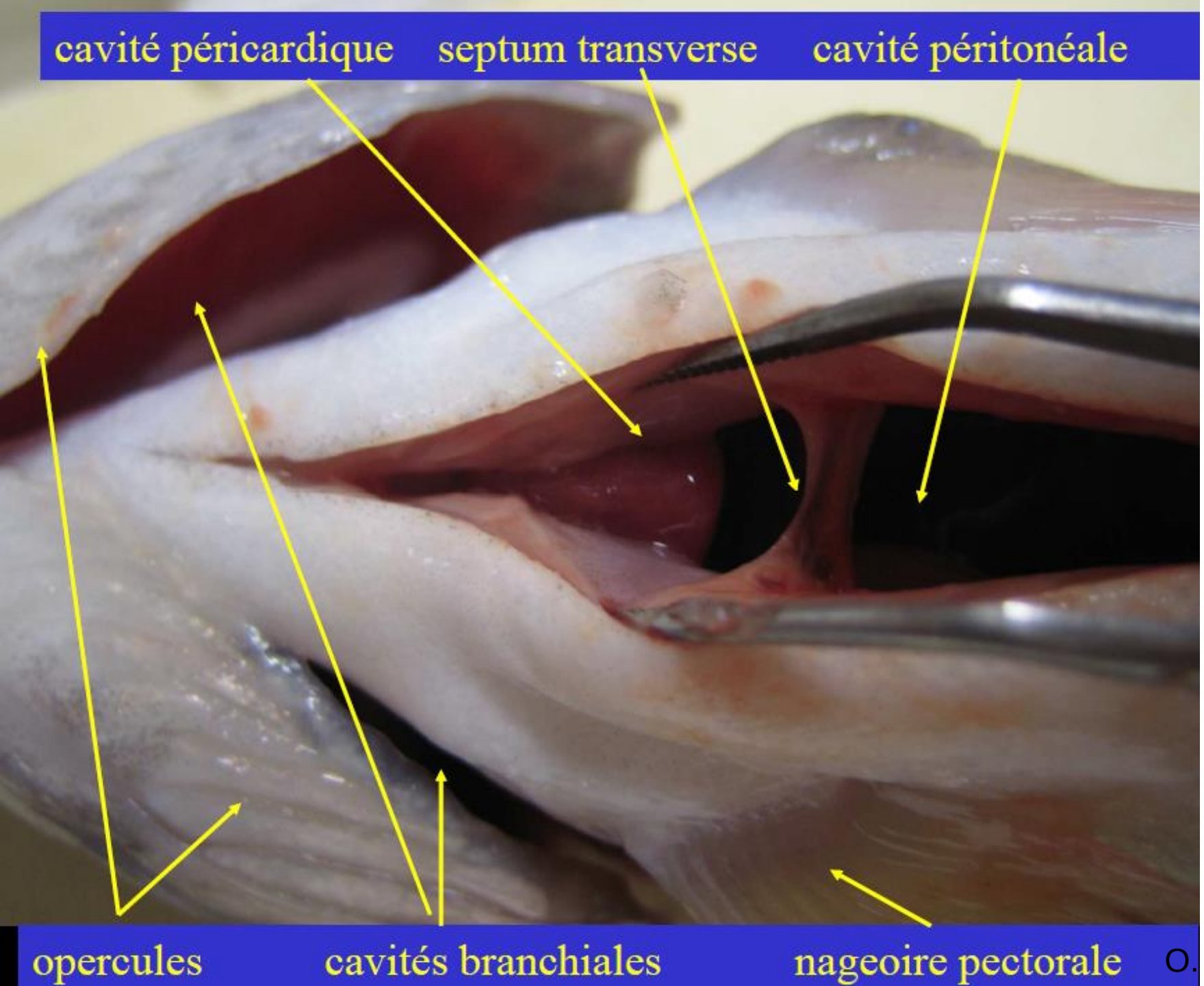
cavité péricardique
septum transverse
cavité péritonéale
opercules
cavités branchiales
nageoire pectorale

O. Mottet

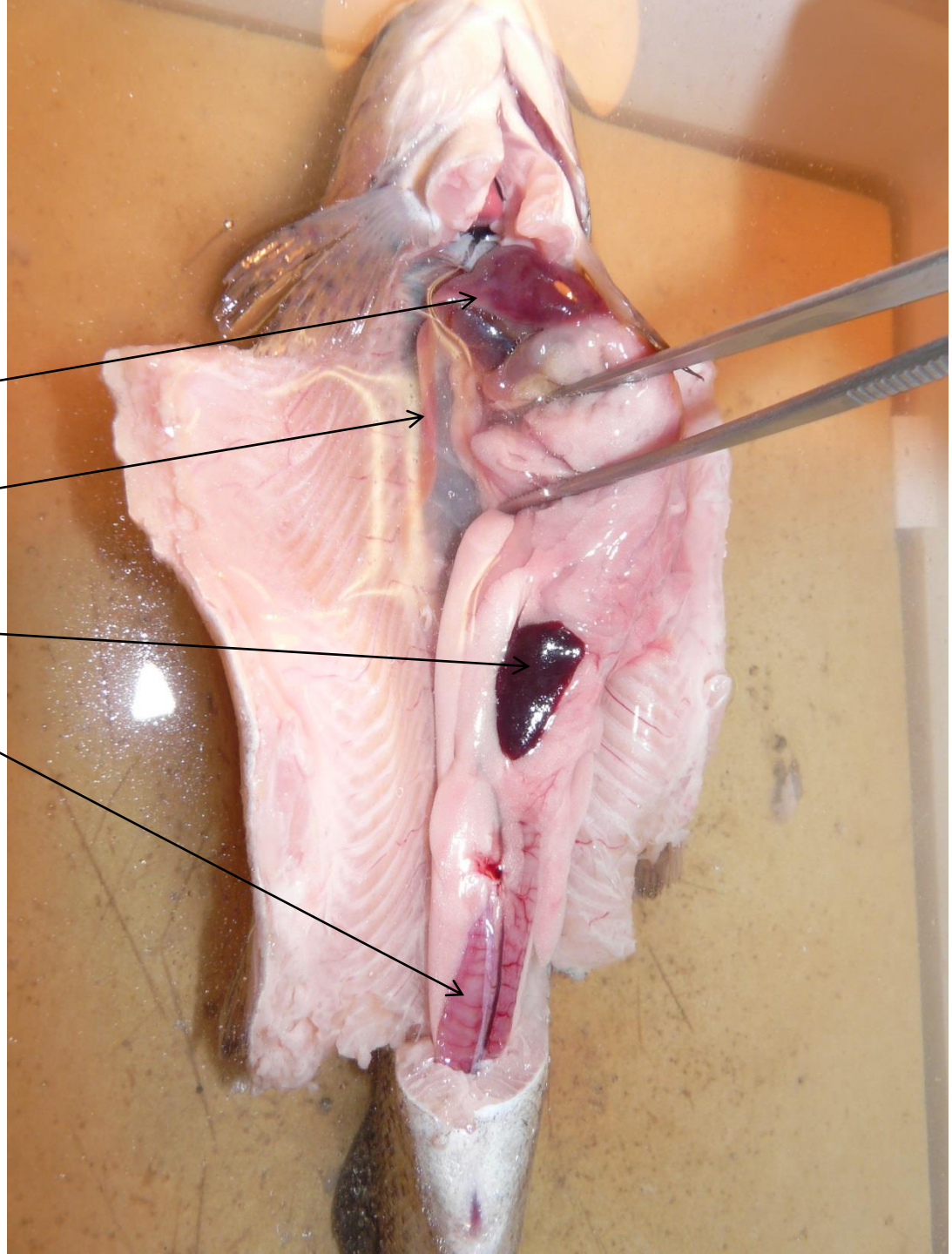
Foie
Ovaire
Rate
Tube digestif

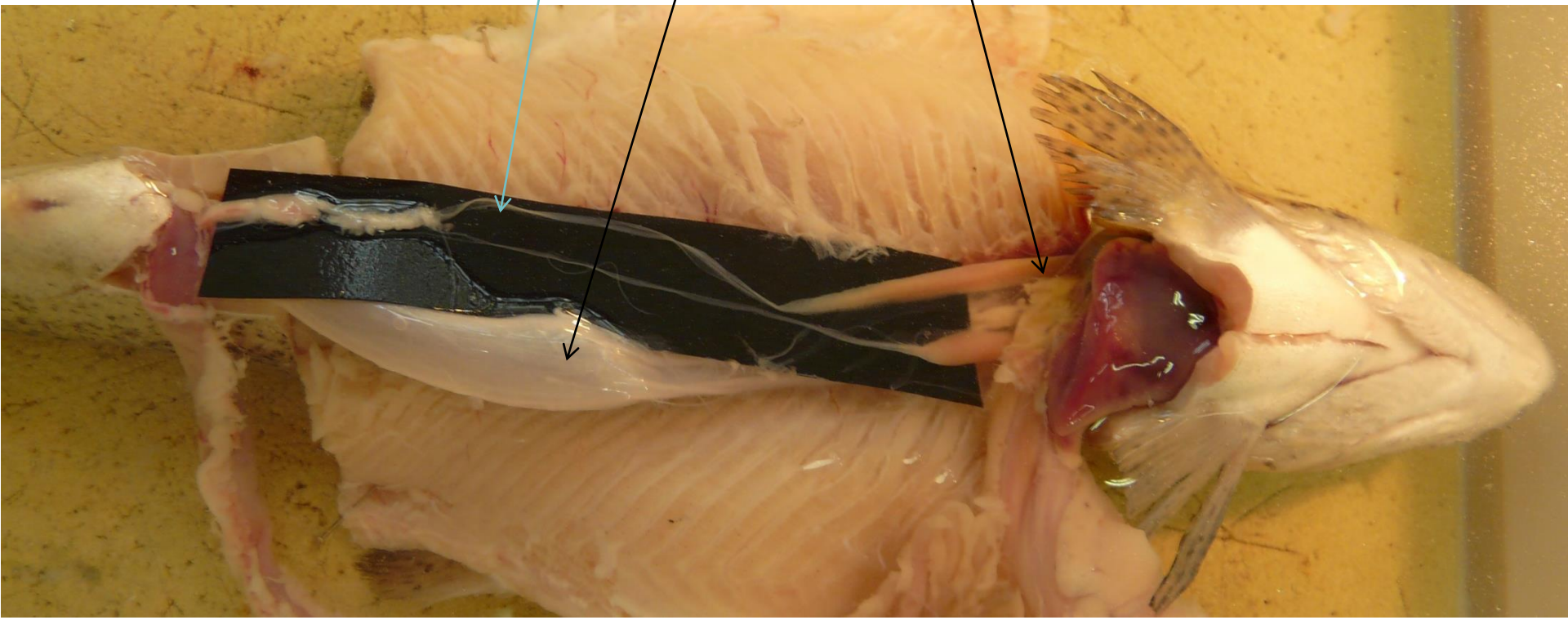
Ovaire
Oviducte
Vessie gazeuse

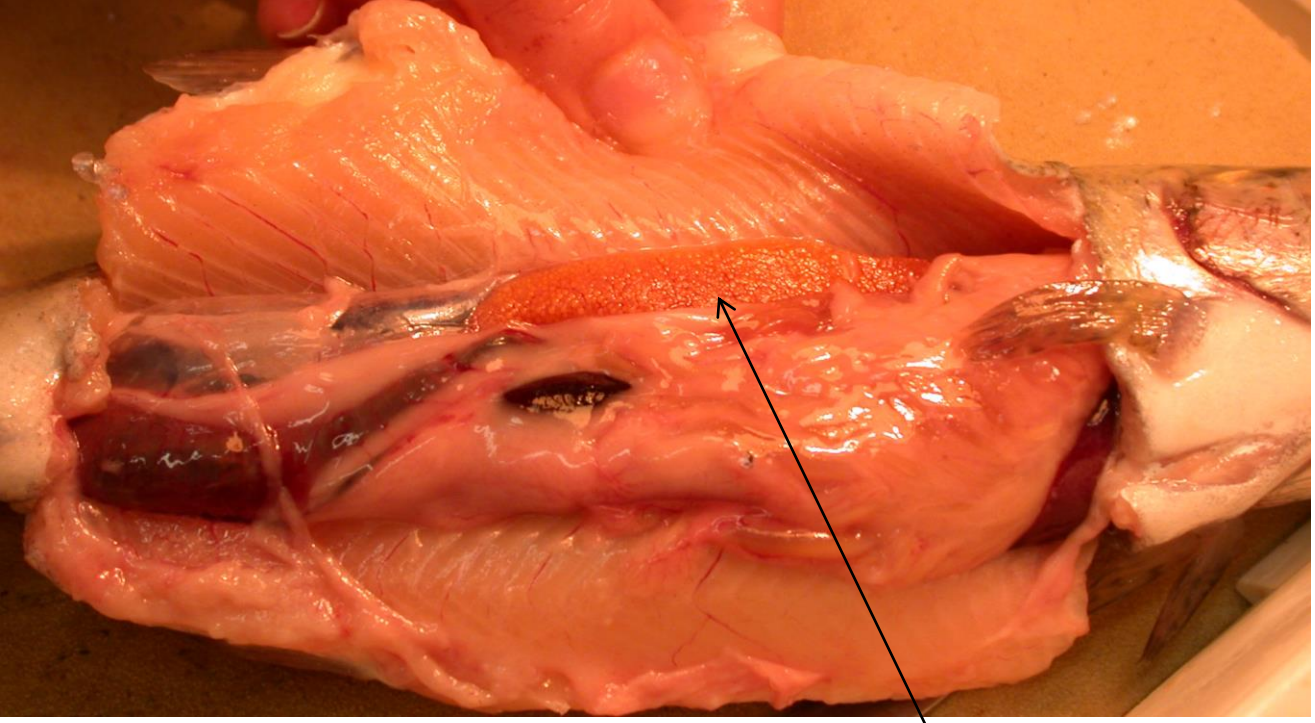

Ovaire

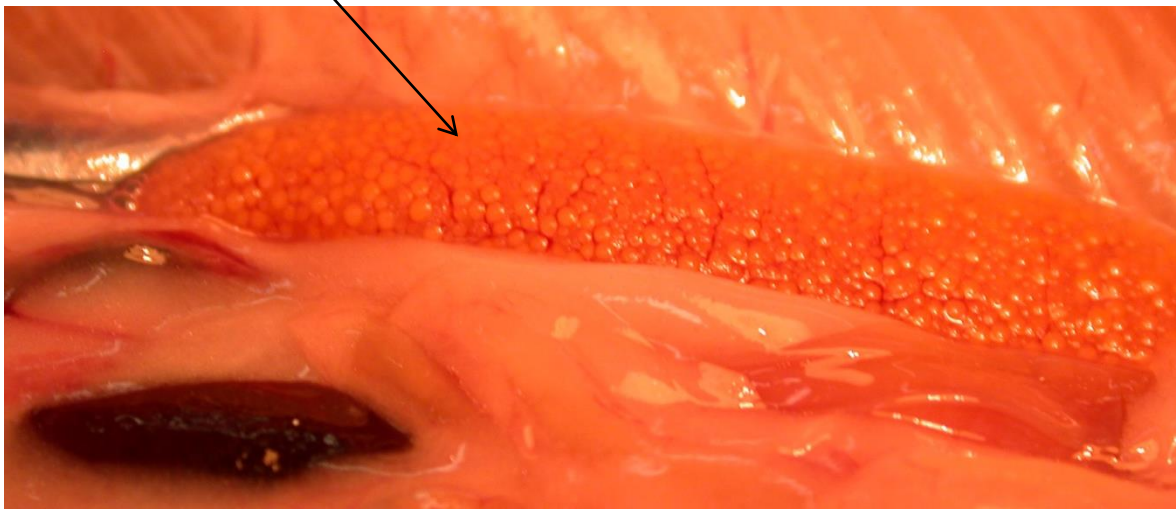

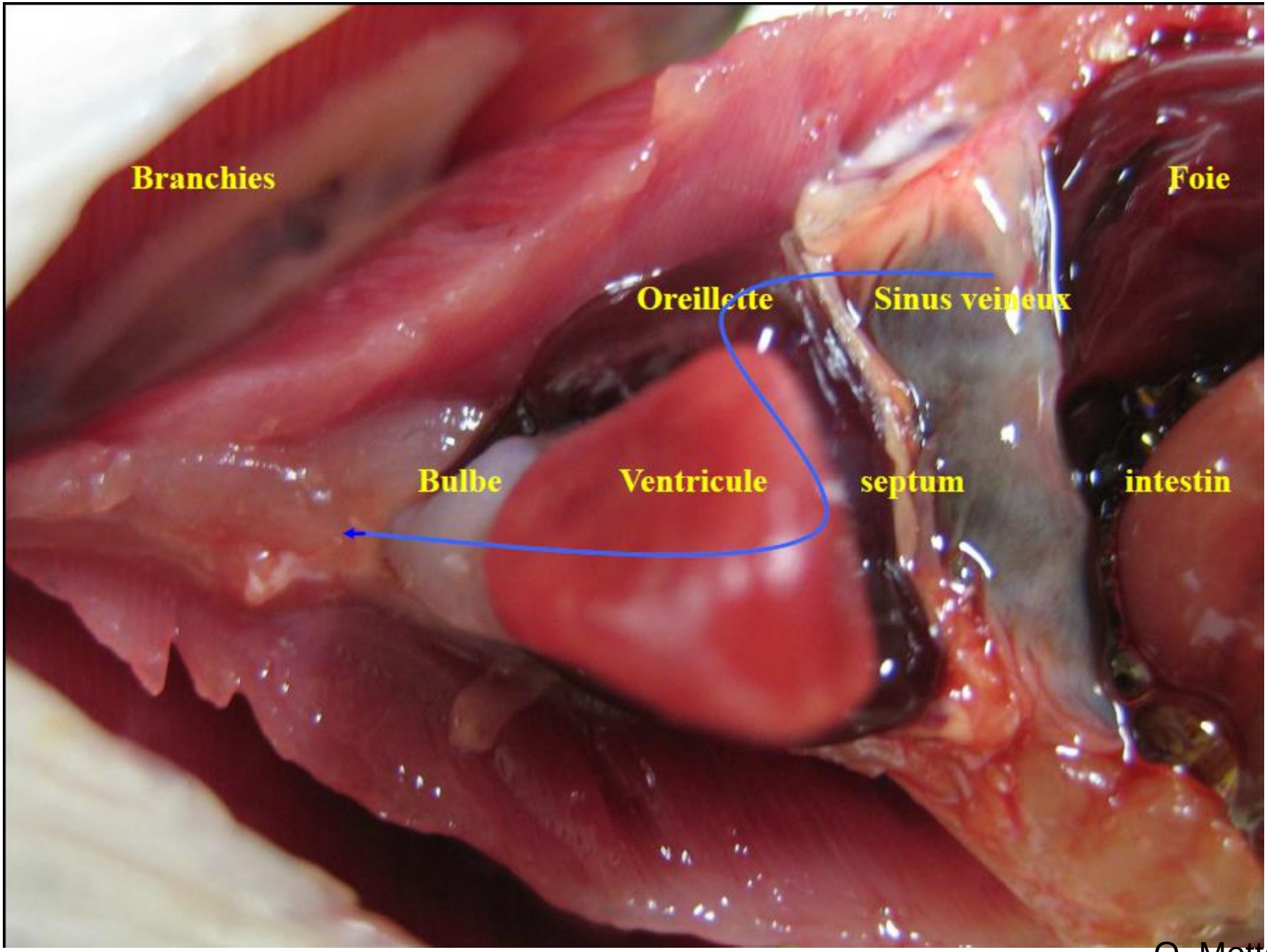
Branchies
Foie
Oreillette
Sinus veineux
Bulbe
Ventricule
septum
intestin

O. Mottet

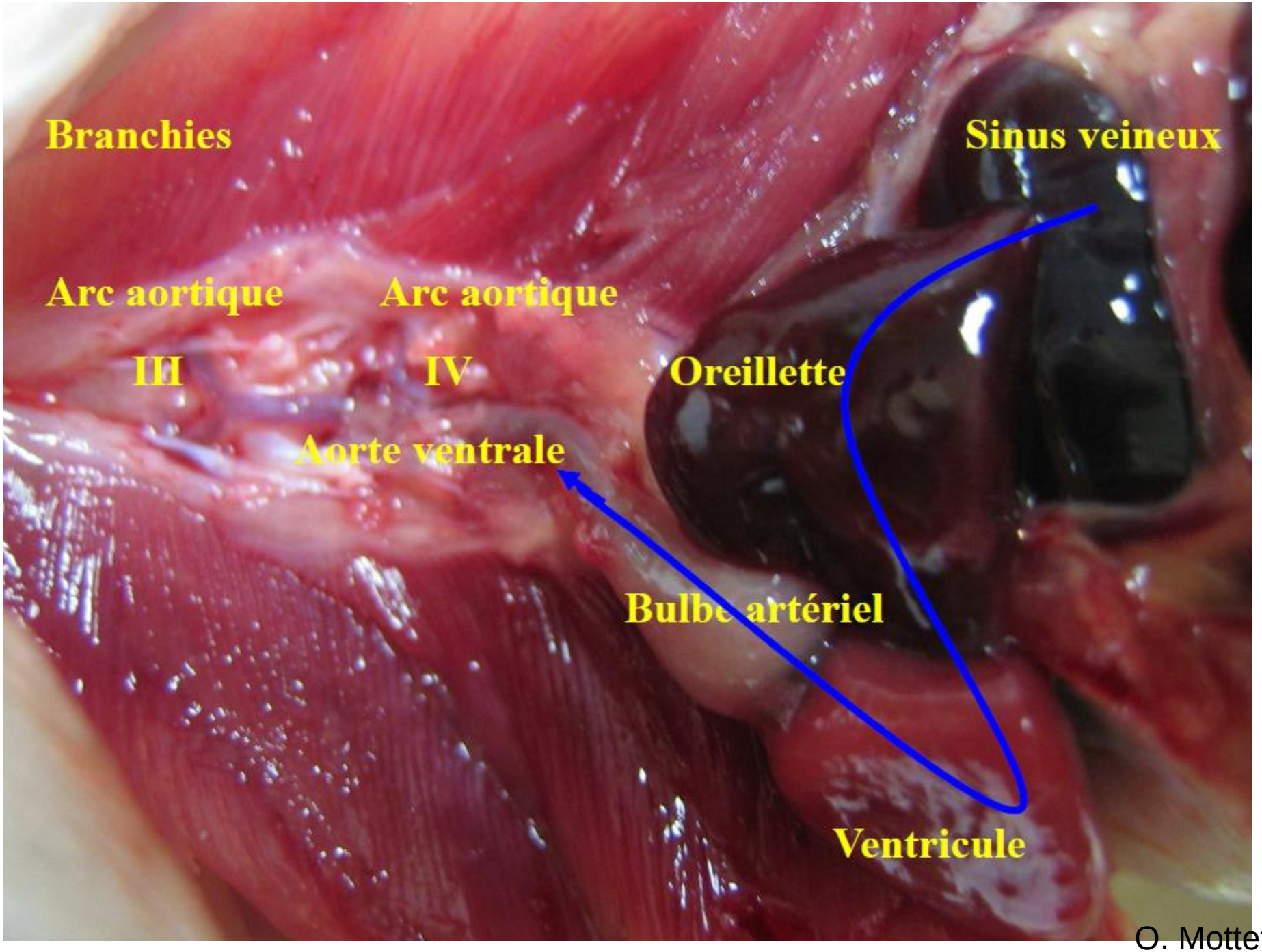
Branchies
Sinus veineux
Arc aortique
Arc aortique
III
IV
Oreillette
Aorte ventrale
Bulbe artériel
Ventricule

O. Mottet

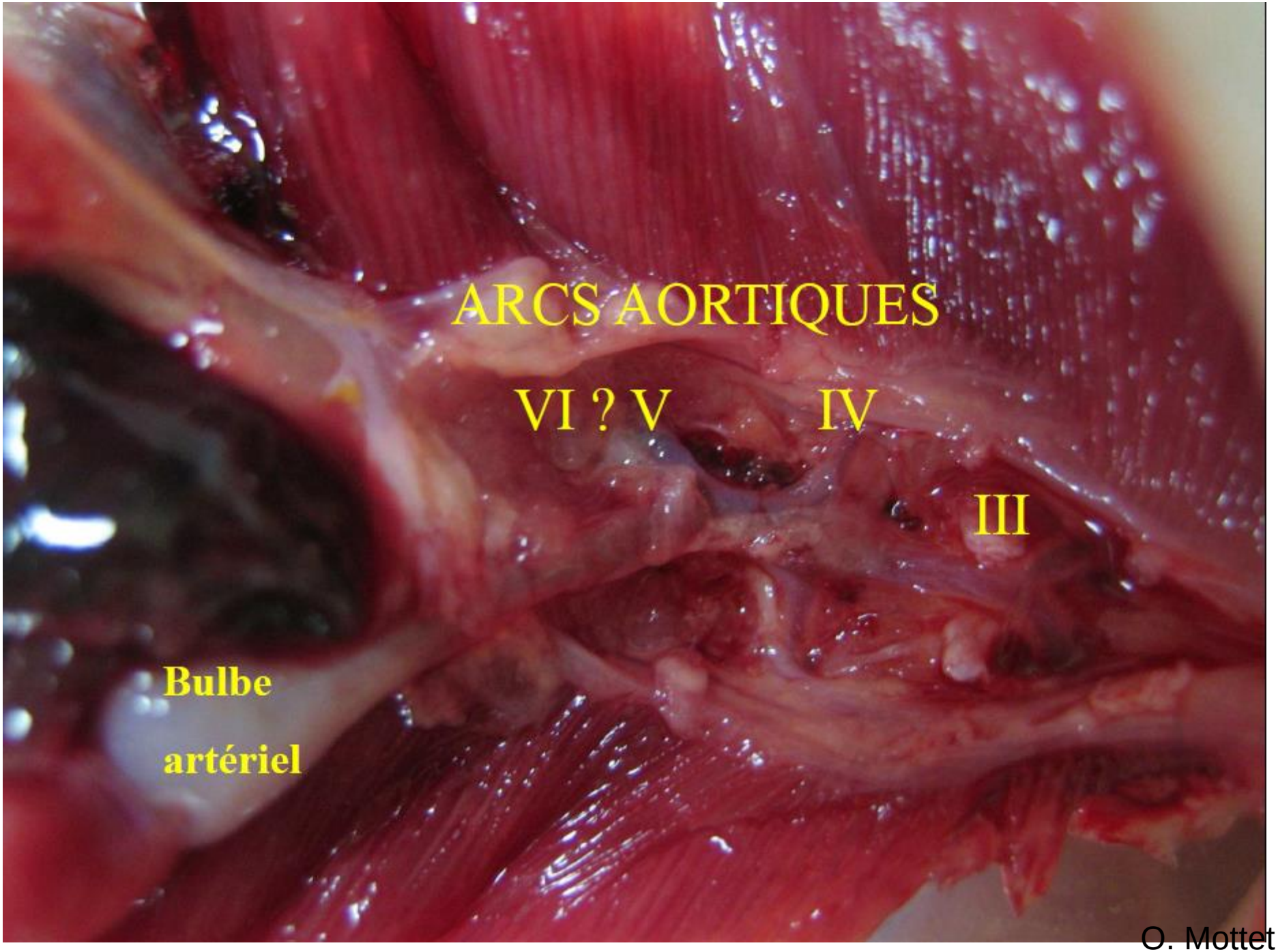

O. Mottet

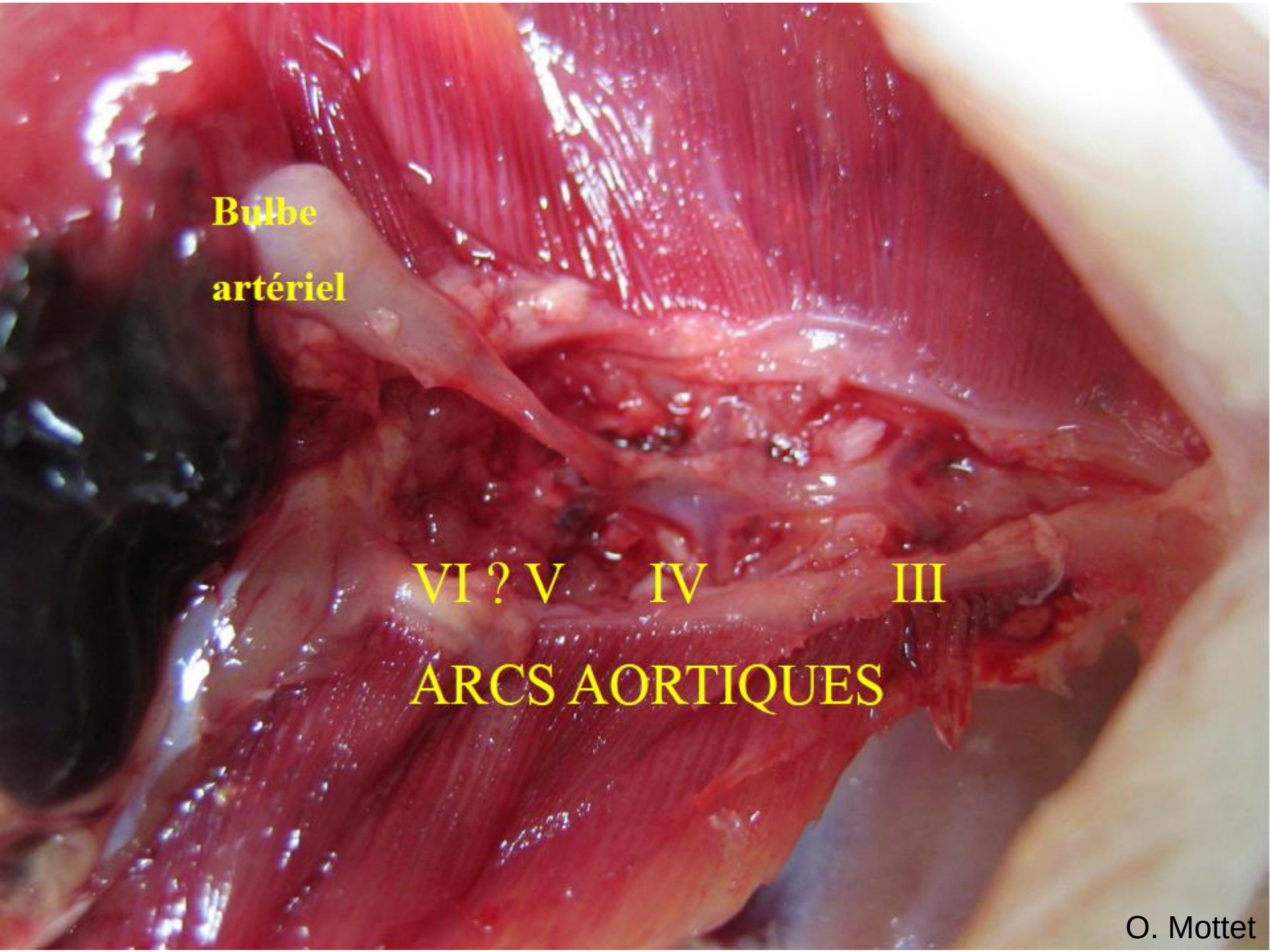

O. Mottet

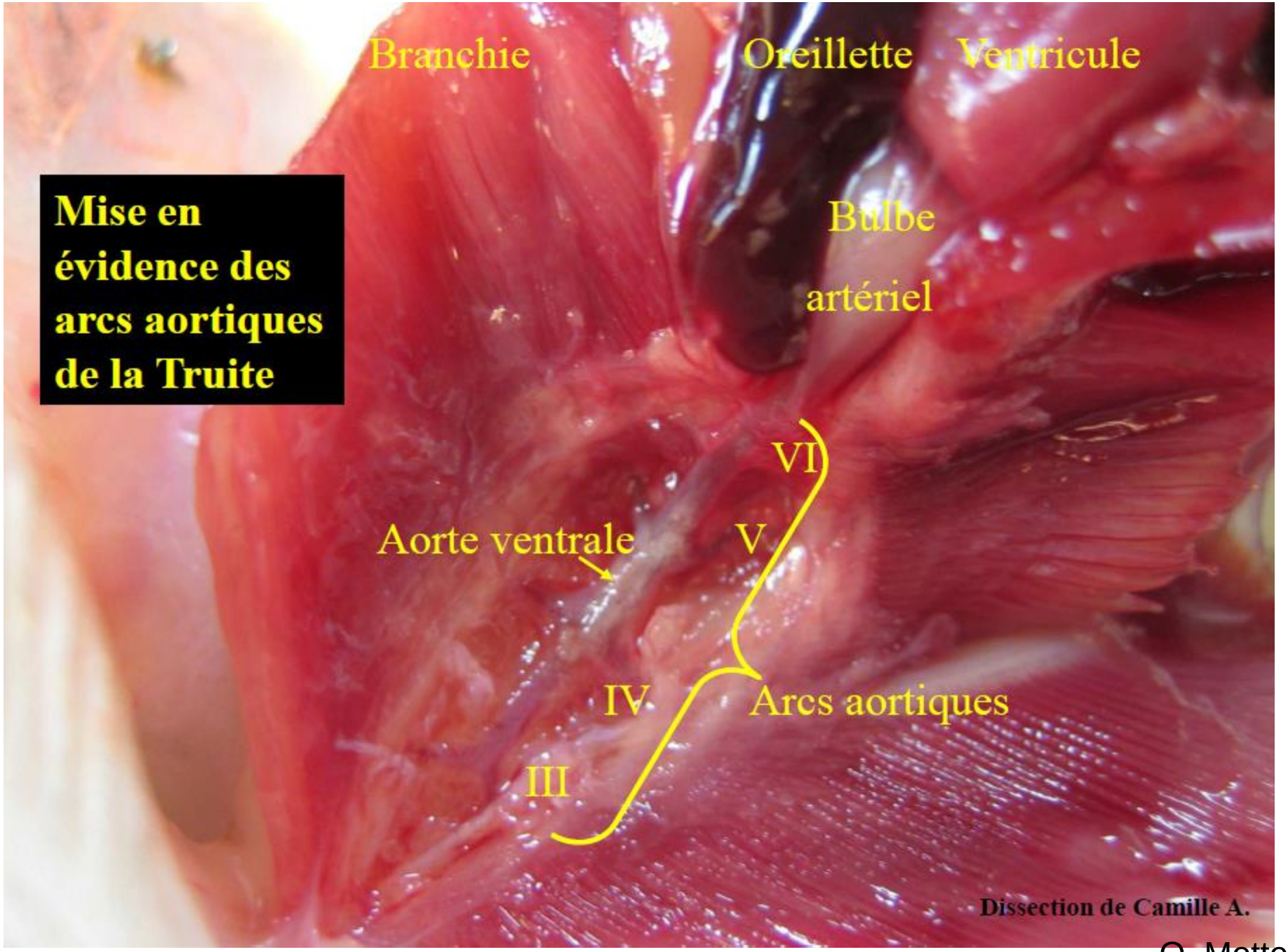
Mise en évidence des arcs aortiques de la Truite
Branchie
Oreillette
Ventricule
Bulbe artériel
VI
V
Aorte ventrale
IV
Arcs aortiques
III
Dissection de Camille A.

O. Mottet

Arcs aortique après injection de bleu de charge
(photo Thomas Bonnafé)

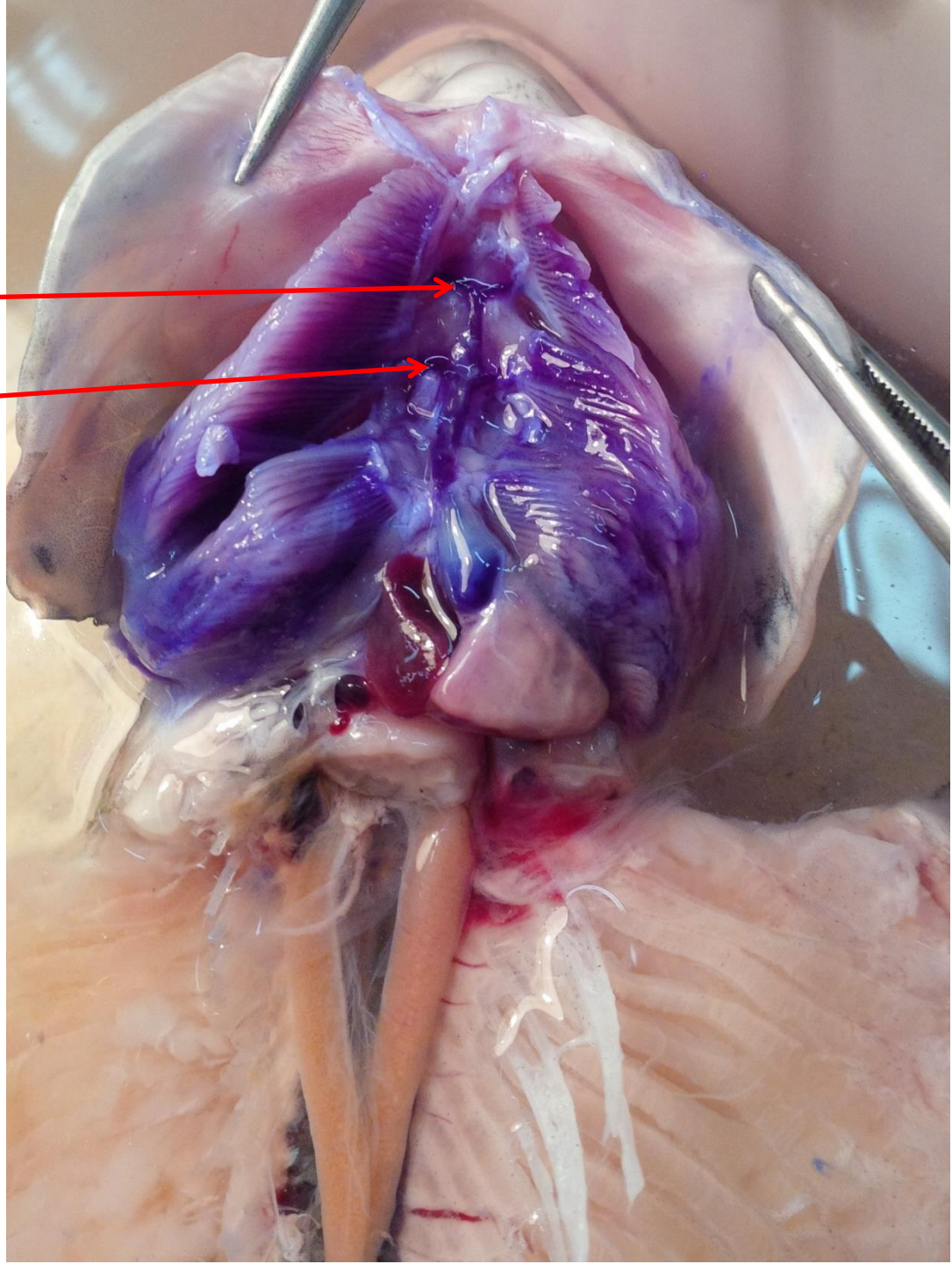

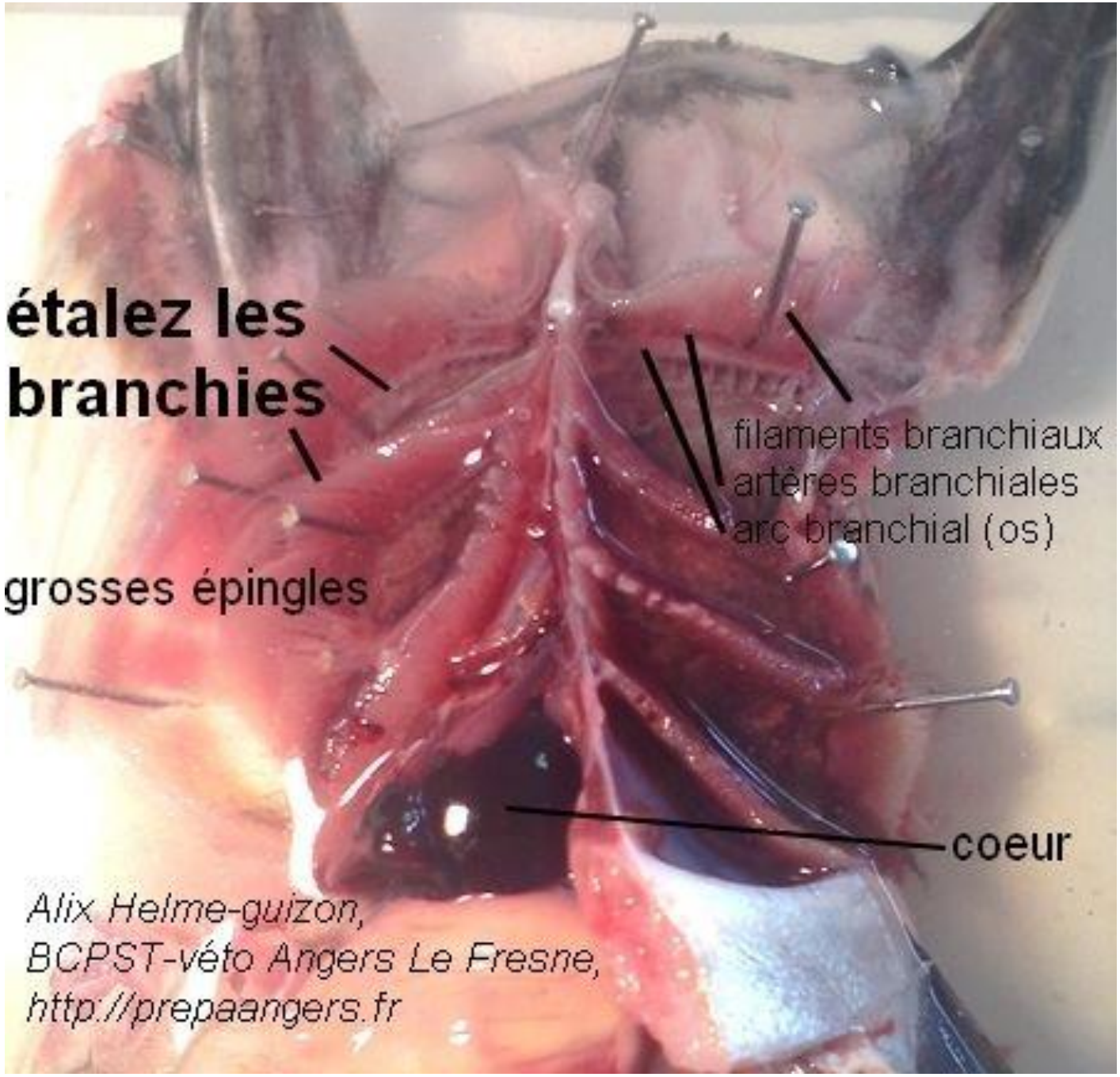
étalez les branchies
grosses épingles
filaments branchiaux
artères branchiales
arc branchial (os)
coeur
Alix Helme-guizon,
BCPST-véto Angers Le Fresne,
http://prepaangers.fr

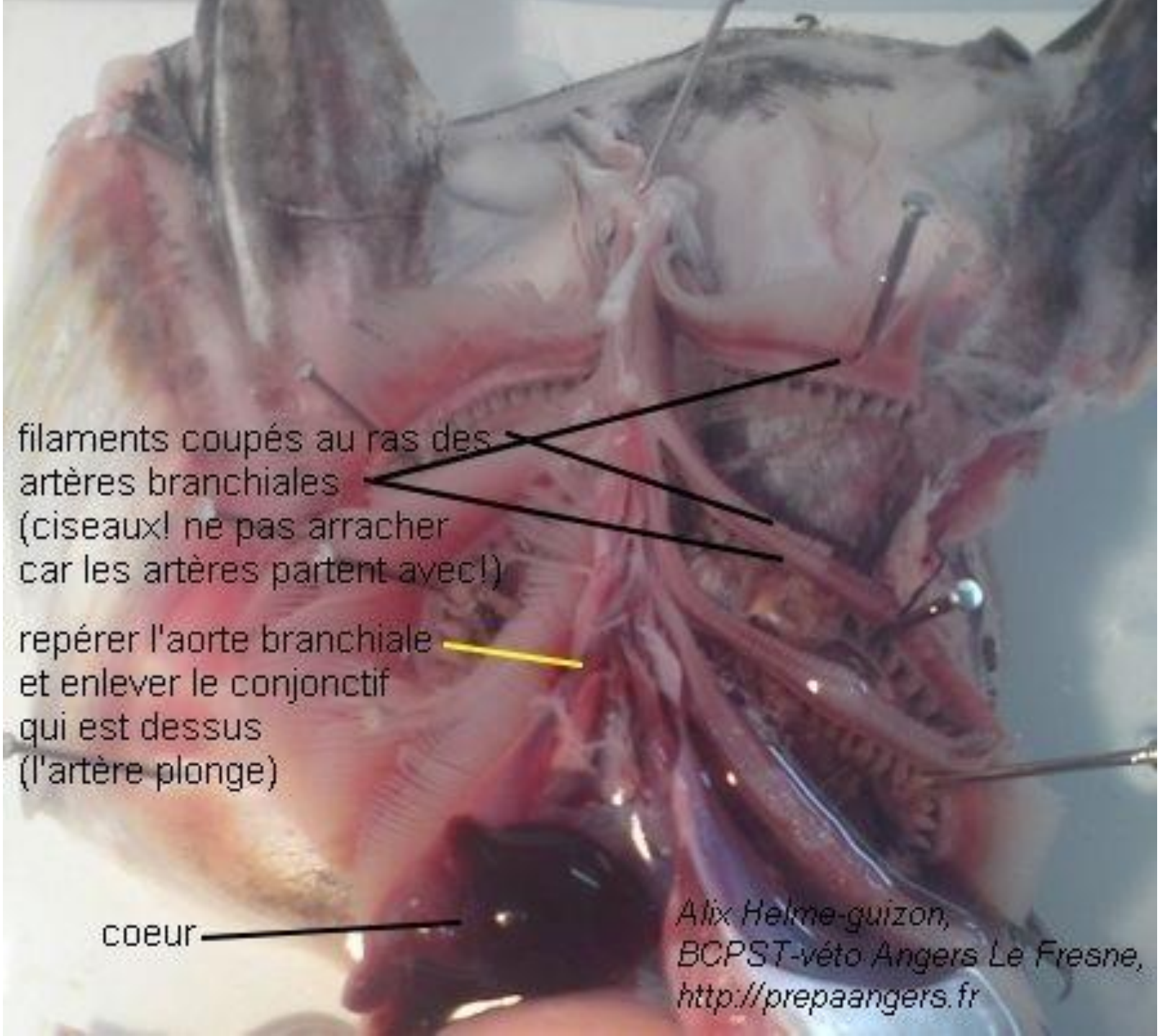
filaments coupés au ras des
artères branchiales
(ciseaux! ne pas arracher
car les artères partent avec!)
repérer l'aorte branchiale
et enlever le conjonctif
qui est dessus
(l'artère plonge)
coeur
Alix Helme-guizon,
BCPST-véto Angers Le Fresne,
http://prepaangers.fr

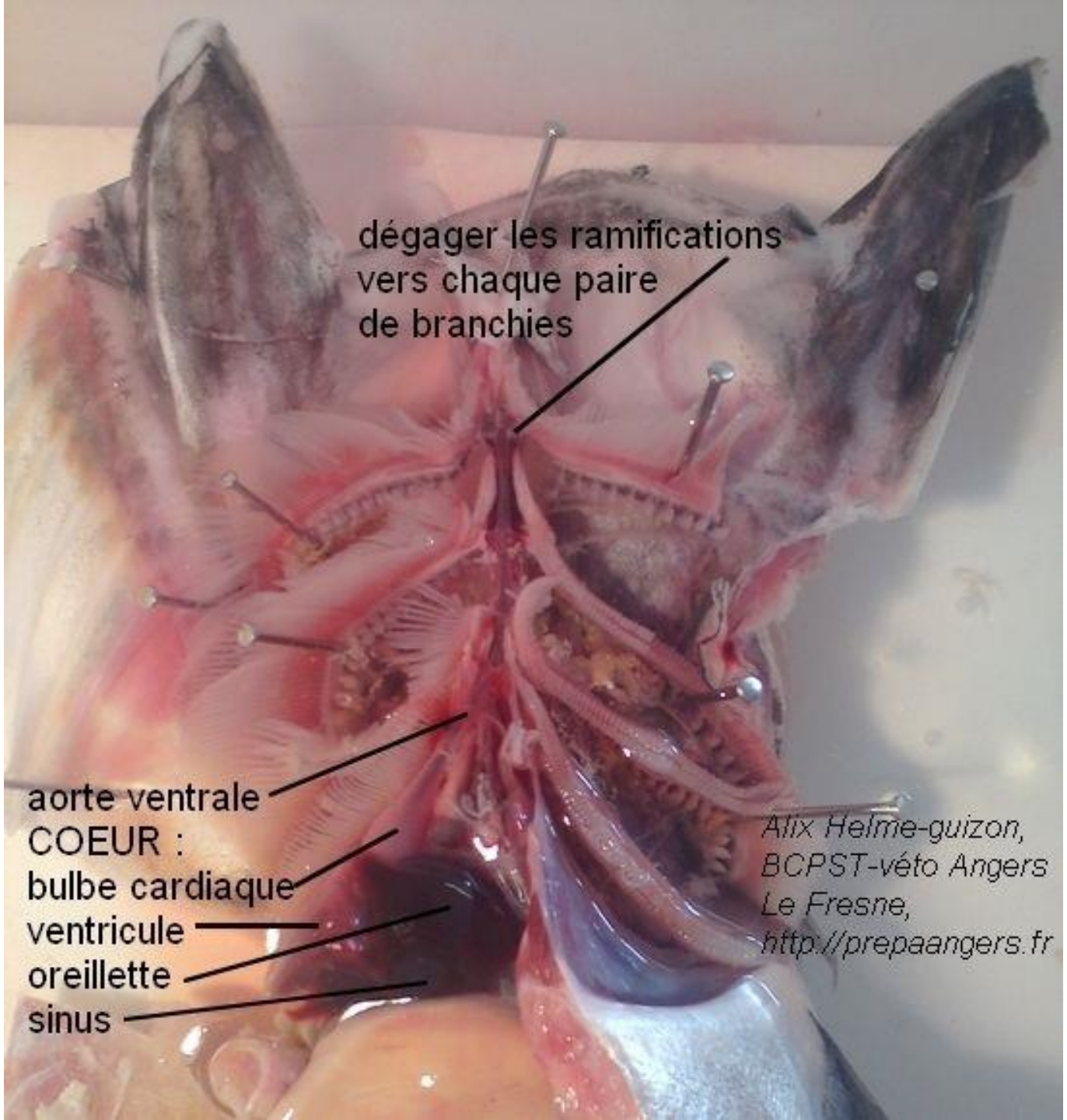
dégager les ramifications
vers chaque paire
de branchies
aorte ventrale
COEUR :
bulbe cardiaque
ventricule
oreillette
sinus
Alix Helme-guizon,
BCPST-véto Angers
Le Fresne,
http://prepaangers.fr

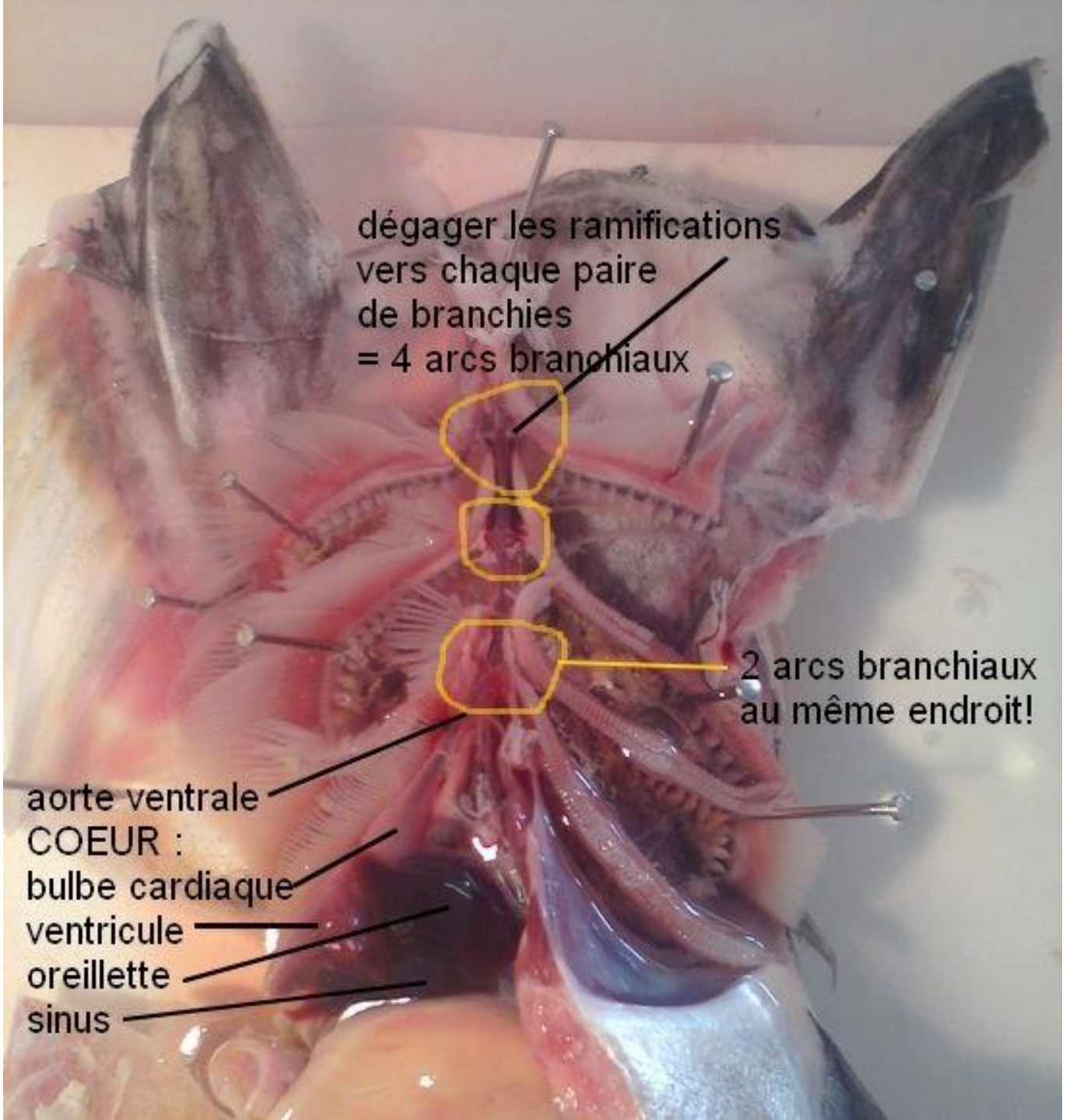
dégager les ramifications
vers chaque paire
de branchies
= 4 arcs branchiaux
2 arcs branchiaux
au même endroit!
aorte ventrale
COEUR :
bulbe cardiaque
ventricule
oreillette
sinus

Figure 9 Vue latérale gauche schématique
de l'appareil circulatoire d'un poisson

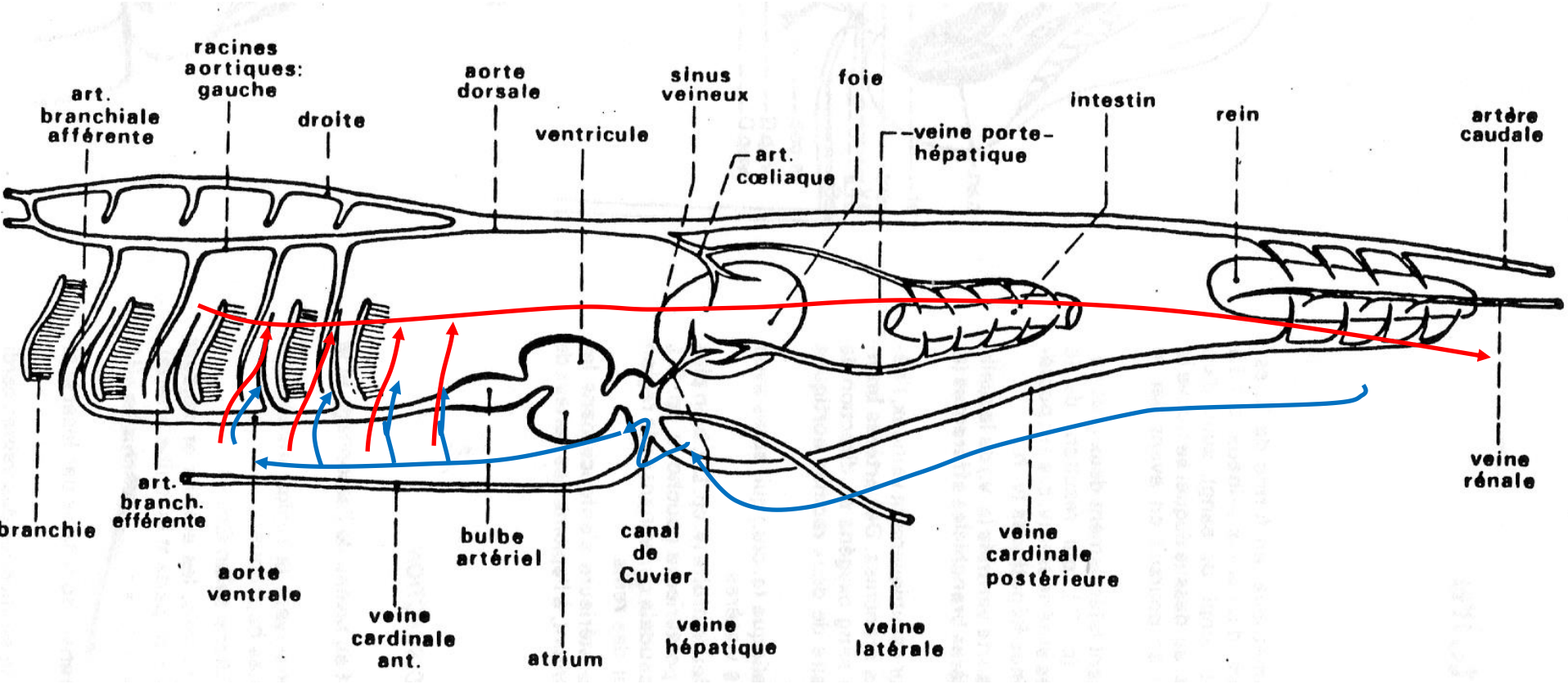

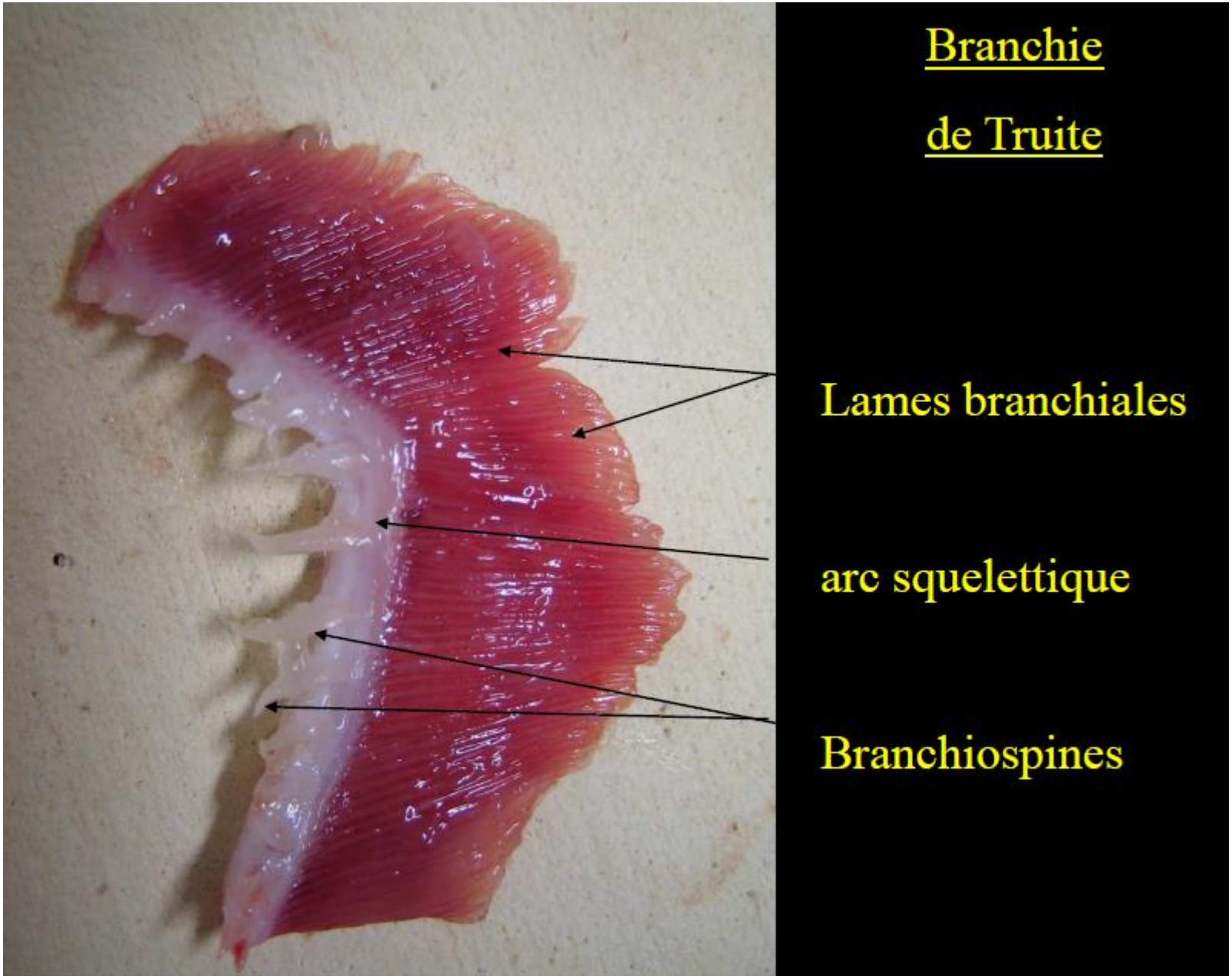
Branchie
de Truite
Lames branchiales
arc squelettique
Branchiospines

O. Mottet

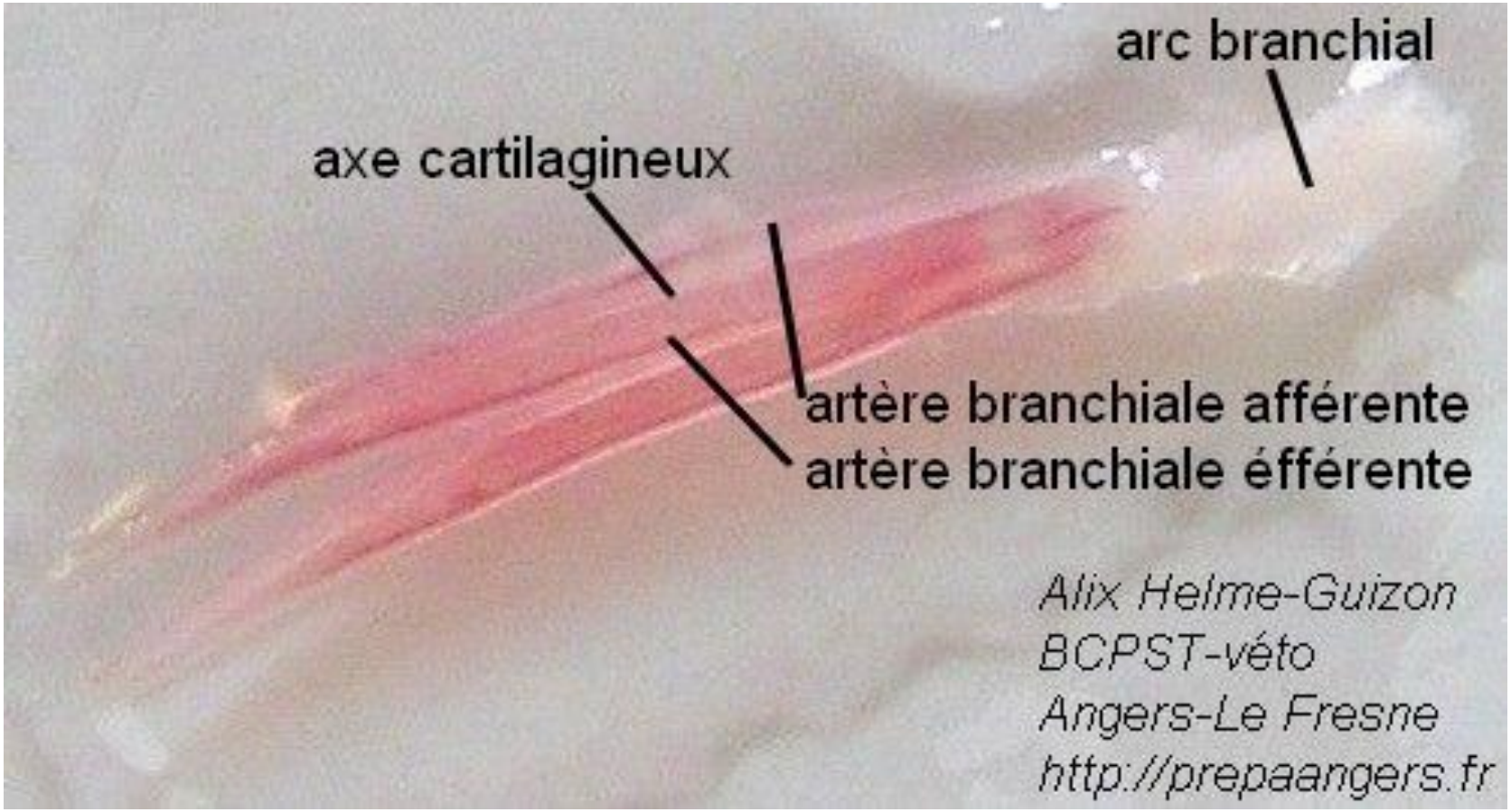
arc branchial
axe cartilagineux
artère branchiale afférente
artère branchiale éfférente
Alix Helme-Guizon
BCPST-véto
Angers-Le Fresne
http://prepaangers.fr

Histologie de la branchie (M.O. x 40)

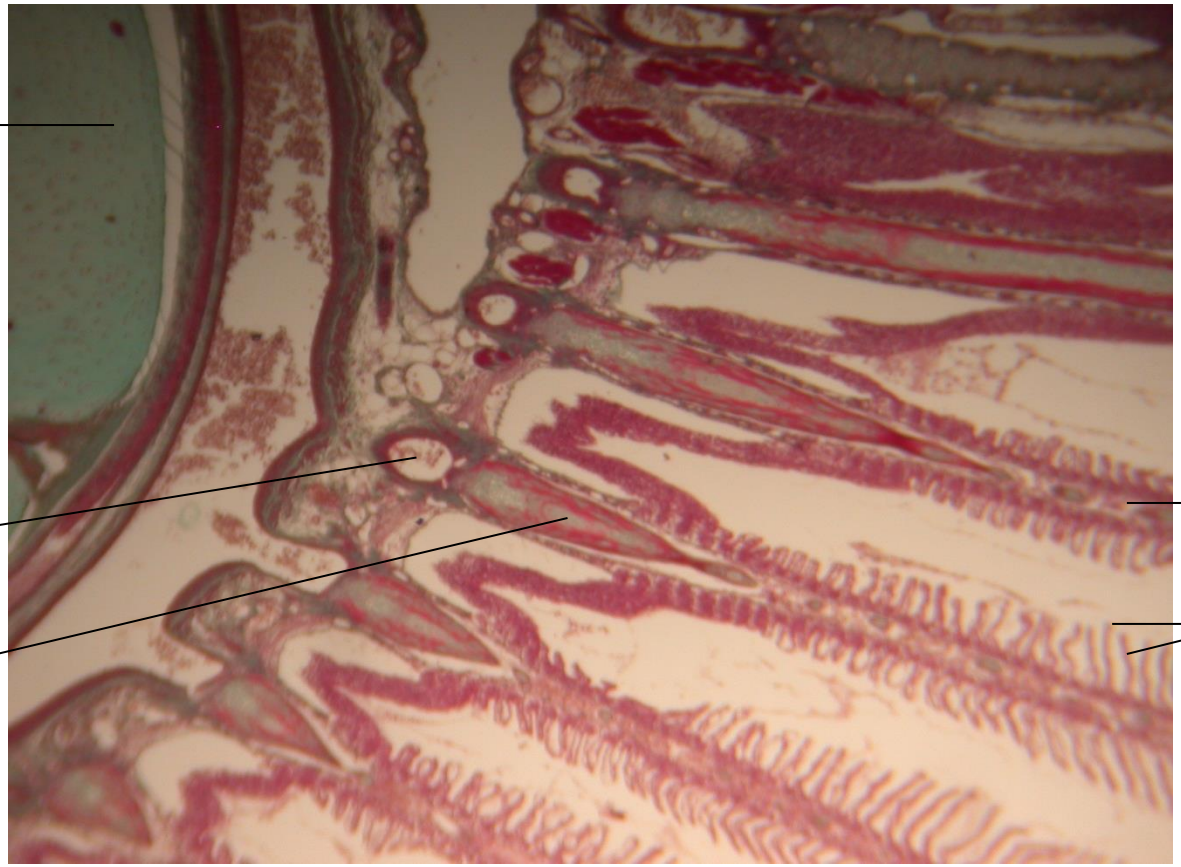

Détail d'une portion de lame branchiale (M.O. x 100)

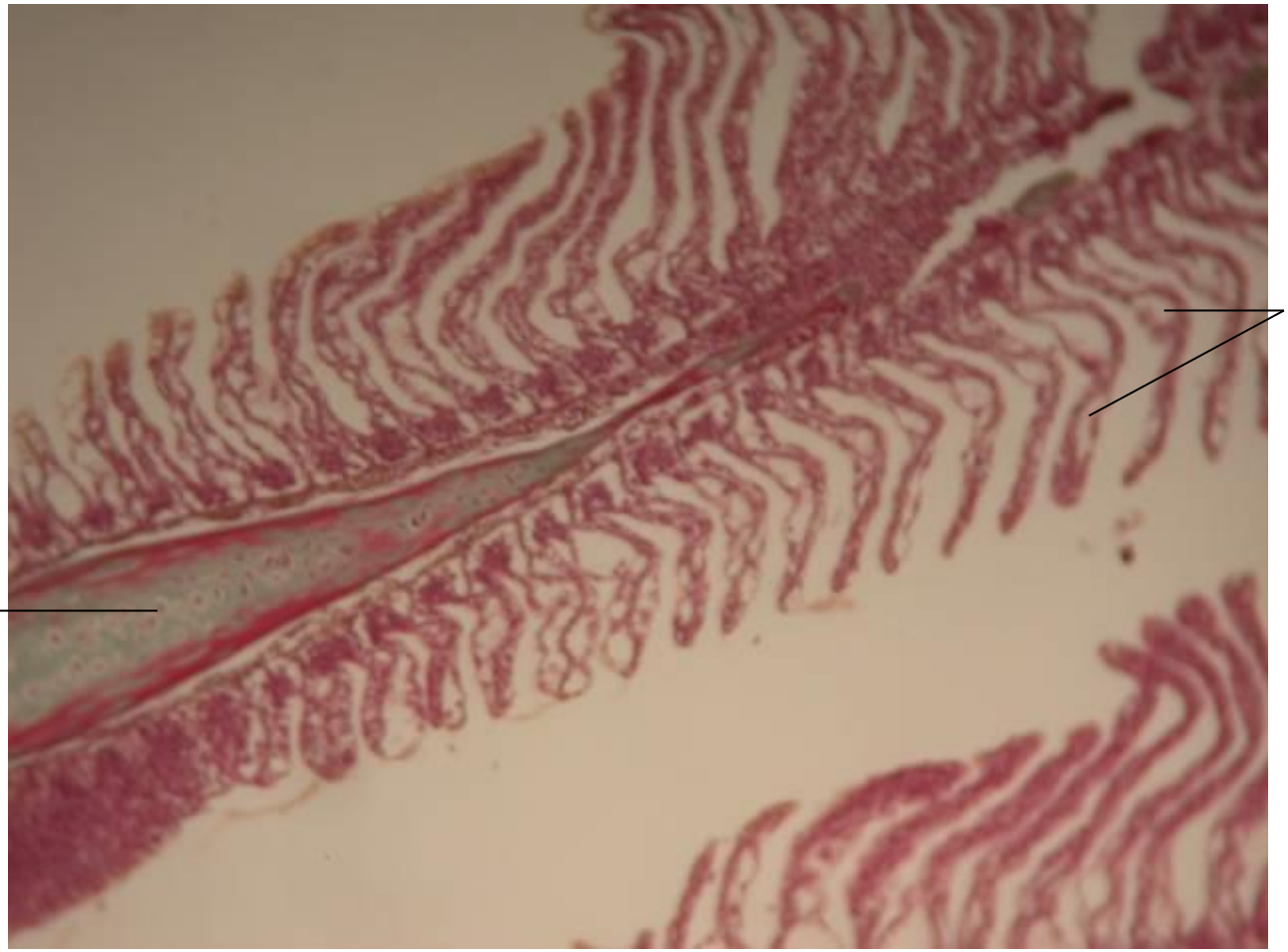

Région des branchies

Dissection
de Céleste Floury

arc aortique III?

Bulbe artériel

Arc aortique IV ?

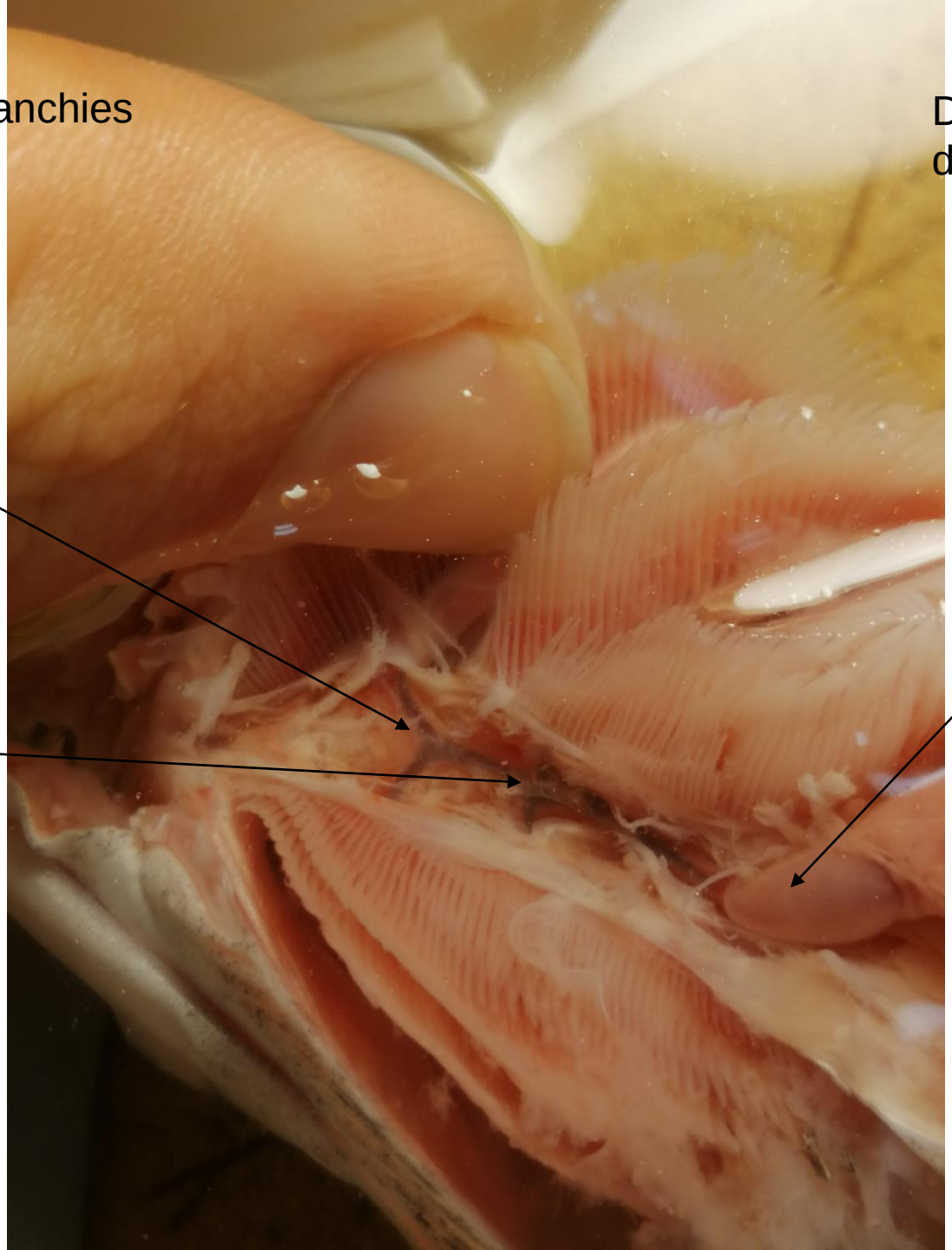
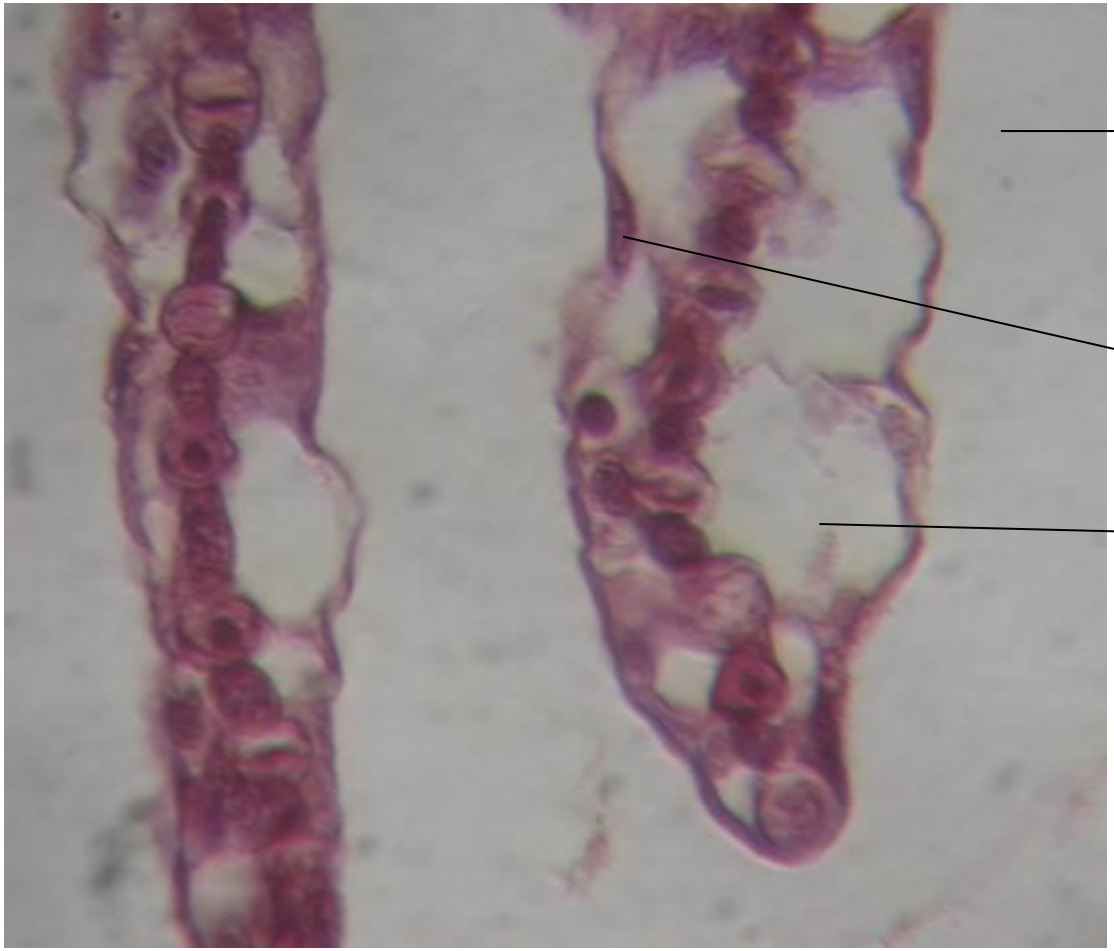
Détail de l'extrémité d'une lamelle branchiale (M.O.x 400)